



**PATIENT**

Graham Generelli

**SPECIES**

Canine

**BREED**

Retriever Mix

**SEX**

Male Neutered

**AGE**

2013

**WEIGHT**

74.5 lbs

**INTERPRETED BY**

Maggie Machen Lamy,  
DVM, DACVIM  
(Cardiology)

**IMAGING PERFORMED BY**

**PRESENTING CLINICAL SIGNS**

History: Acute bradyarrhythmia with pre-medication.  
Echo results (3/2022 EL): NSF  
AUS results (1/2022 MD): NSF

**HOLTER MONITOR FINDINGS AND RHYTHM ASSESSMENT**

Time analyzed	23:31h
Mean heart rate	65bpm
Maximum heart rate	229bpm
Minimum heart rate	31bpm
VPCs	2 singles
APCs	3 singles

Interpretation: Underlying normal sinus rhythm with appropriate rate variation. Two single VPCs and 3 APCs are seen which are of little concern. Singles only with low markers of malignancy. Minimum heart rate is with sleep/rest; no extended pauses or AV block noted. Max heart rate is sinus and occurs with stress/activity. No additional issues are seen.

Rhythm diagnosis: Sinus rhythm with occasional single VPCs and APCs.

**INTERPRETATION OF THE FINDINGS & FURTHER RECOMMENDATIONS**

Holter monitor shows overall normal sinus rhythm with occasional premature beats. VPCs/APCs are generated from abnormal conductive or fibrotic tissue in the heart muscle. Occasional premature beats are considered normal, without carrying significant concern as is the case here. The max and minimum heart rates are normal, and correlate with activity level. No bradyarrhythmias appreciated.

These findings do not explain bradyarrhythmias with pre-medication. A drug reaction is suspected. Consider an alternative protocol, or potentially consultation with or referral to an anesthesiologist.

No treatment is indicated. Monitor for signs of sustained tachyarrhythmias, such as syncope or acute lethargy.

Monitor at home for collapse, exercise intolerance, and/or lethargy.

Recheck ECG and/or holter depending on clinical signs in the future.

**HOSPITAL NAME**

Rockaway AH

**REFERRING VET**

Dr. Maniar

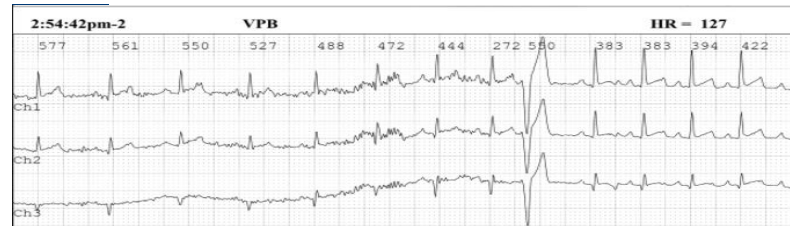**INVOICE**

23300

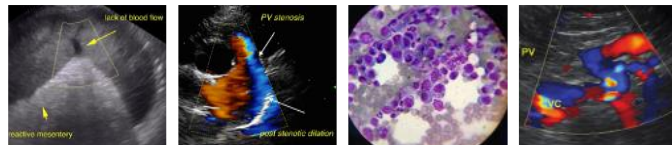
**DATE**

3/28/22

**IMAGES**



VPC with excitement



**PATIENT**

Graham Generelli

**SPECIES**

Canine

**BREED**

Retriever Mix

**SEX**

Male Neutered

**AGE**

2013

**WEIGHT**

74.5 lbs

**INTERPRETED BY**

Maggie Machen Lamy,  
DVM, DACVIM  
(Cardiology)

**IMAGING PERFORMED BY**

**HOSPITAL NAME**

Rockaway AH

**REFERRING VET**

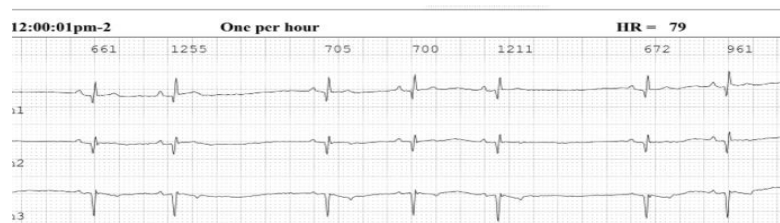Dr. Maniar

**INVOICE**

23300

**DATE**

3/28/22



RSA with sleep

The information and recommendations provided are based on the images presented by the referring veterinarian. No evaluation can be communicated regarding pathology that was not visible in the image/video clips provided.

Thank you for this referral. If the clinical or image interpretation does not parallel your findings or if I can be of any further assistance please contact me.

Maggie Machen Lamy, DVM  
Diplomate of the American College of Veterinary Internal Medicine (Cardiology)  
info@sonopath.com